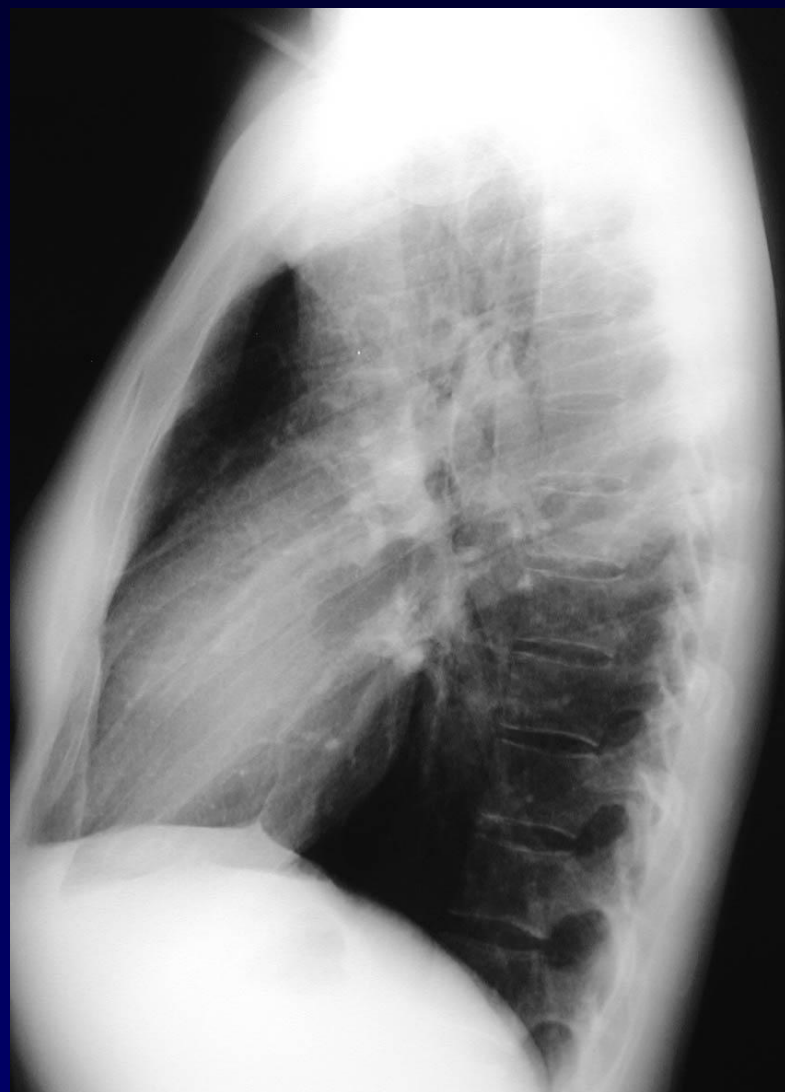
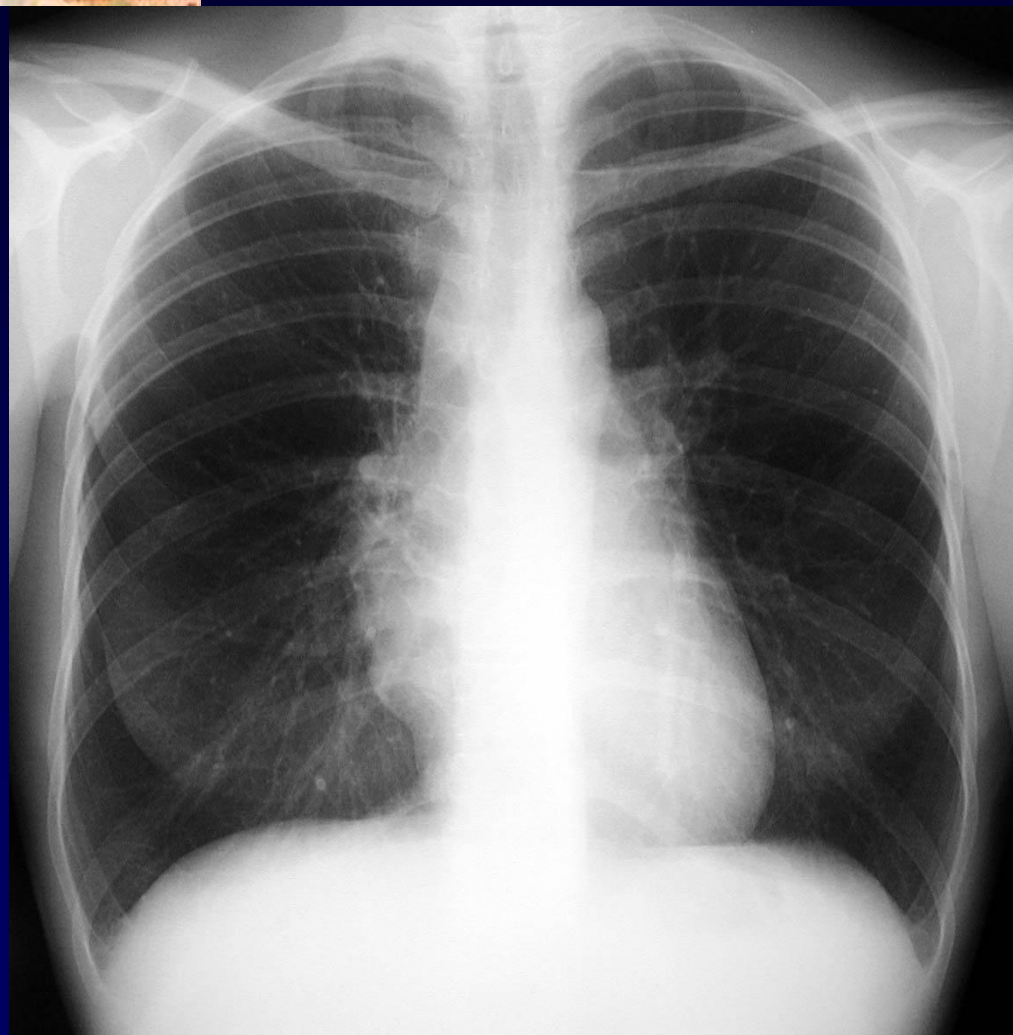

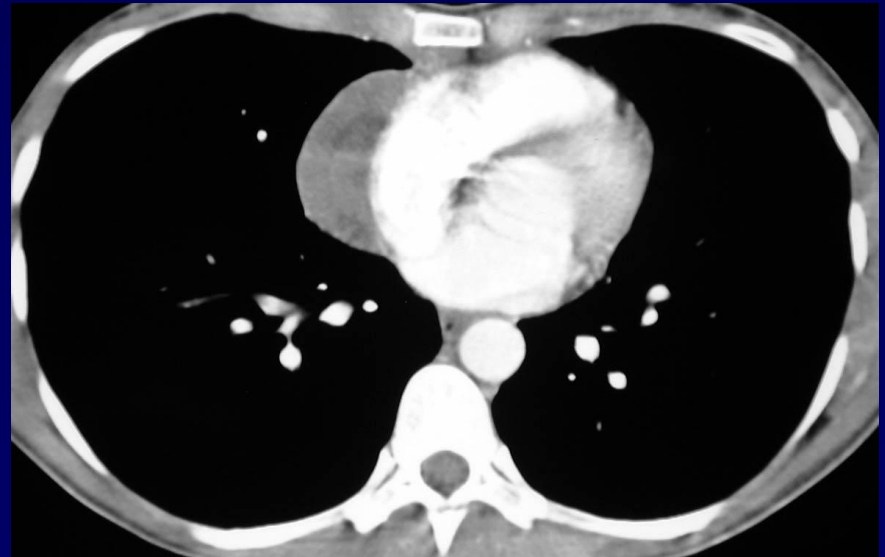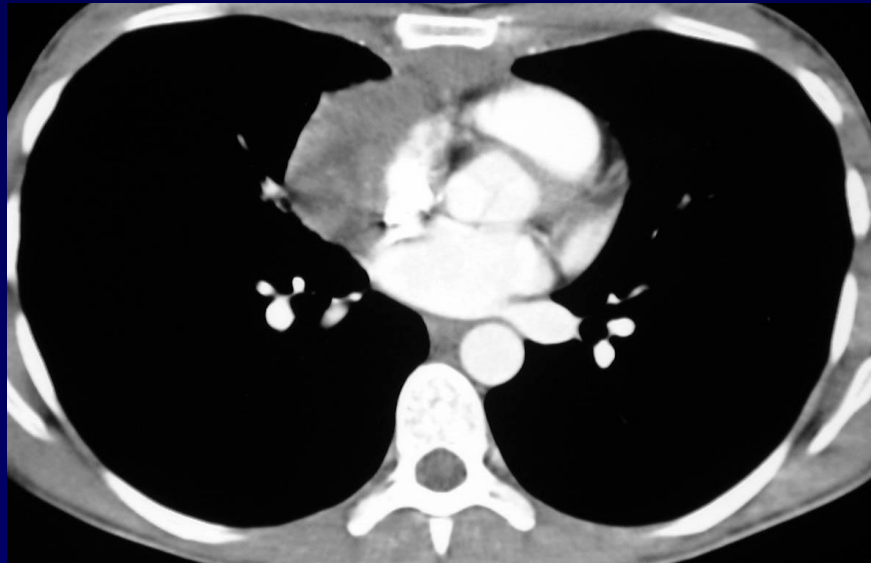
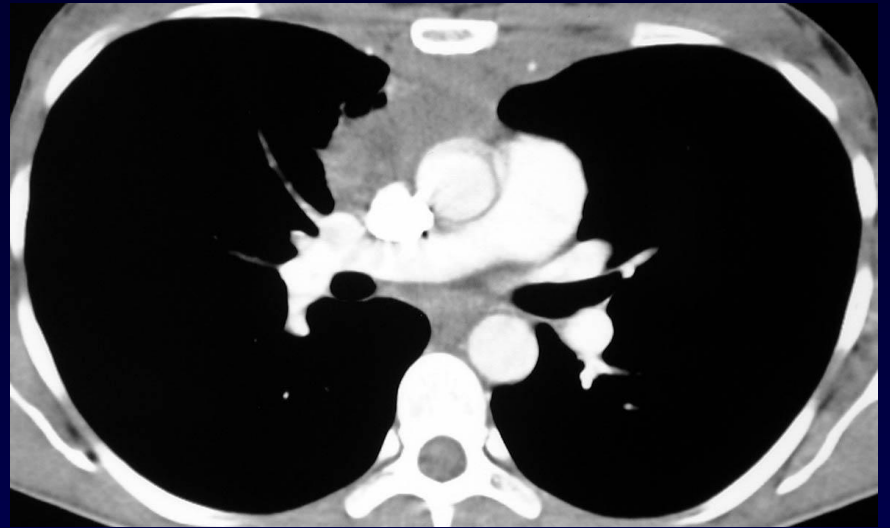


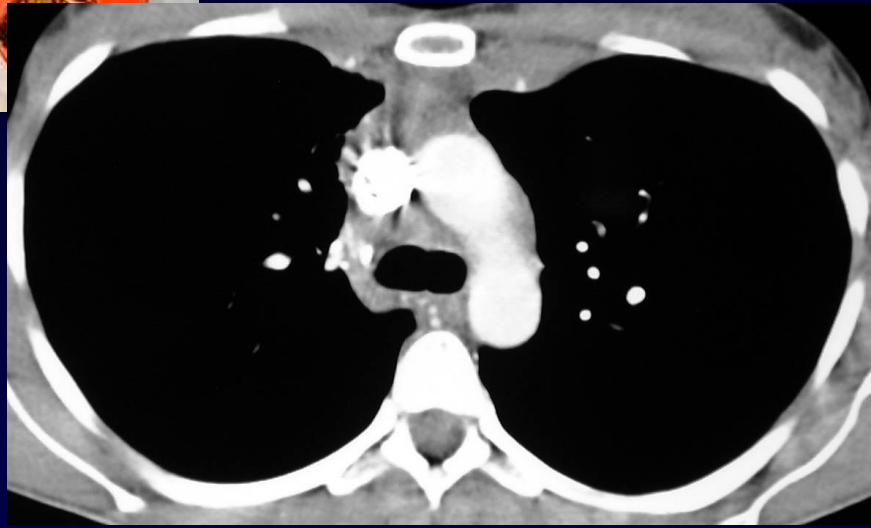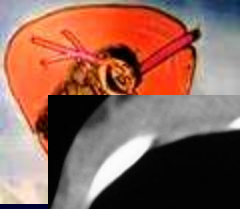J GIRON

Femme de 35 ans

Bilan d'adénopathies cervicales droites







Diagnostic ?



Tumeur thymique à extension paracardiaque droite

Séméiologie du cliché standard+++